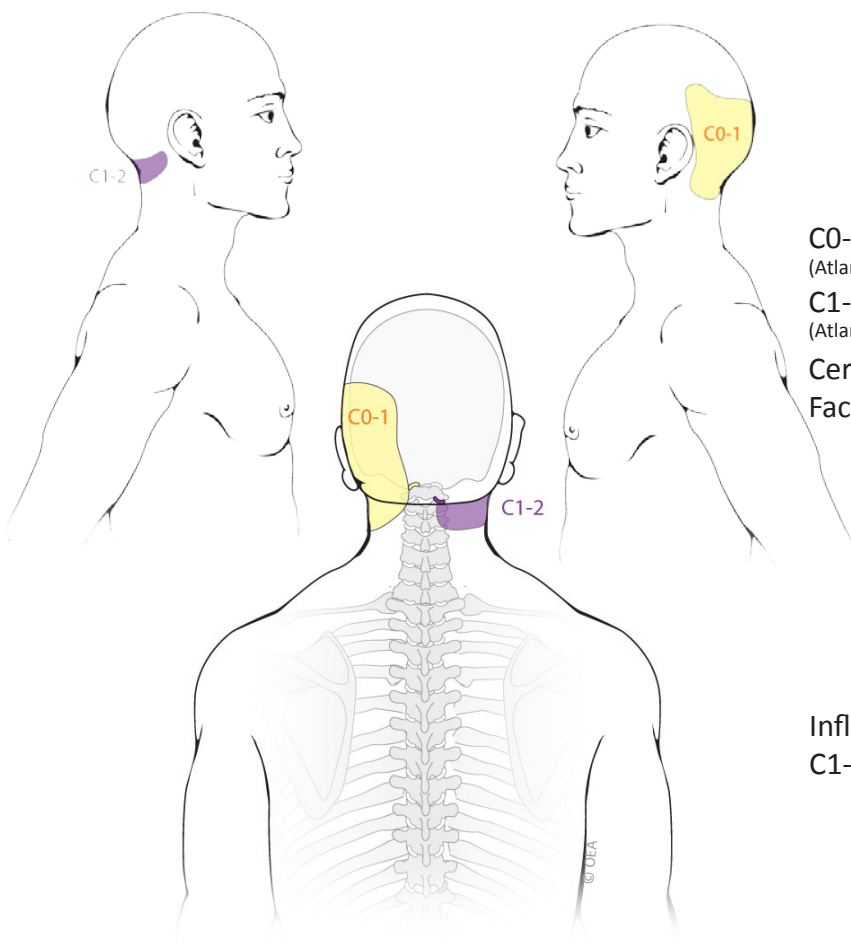
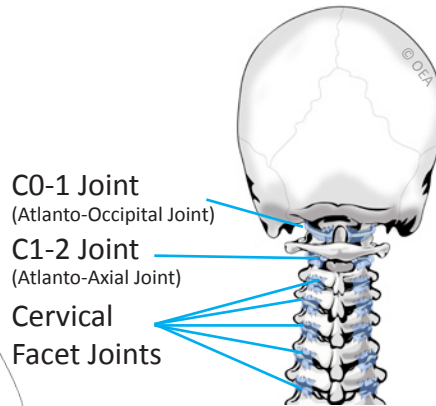


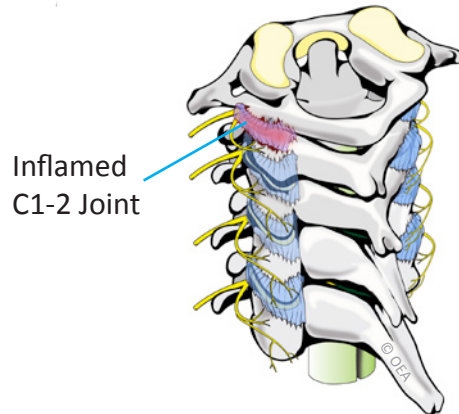
C0-1 and C1-2 Joint Pain Patterns



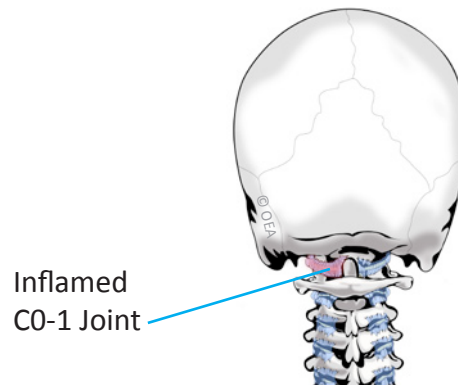
Normal Anatomy



C1-2 Synovitis



C0-1 Synovitis



Based on: Dreyfuss P, Michaelsen M, Fletcher D. Atlanto-occipital and lateral atlanto-axial joint pain patterns. *Spine*. 1994; 19(10):1125-31.

TOUCHSTONE
INTERVENTIONAL PAIN CENTER

Shawn Sills, MD

Anesthesiologist
Specializing in Interventional Pain Management
American Board of Anesthesiology
American Board of Pain Medicine
Fellow of Interventional Pain Practitioners (World Institute of Pain)
American Board of Interventional Pain Physicians
American Board of Addiction Medicine

2925 Siskiyou Boulevard
Medford, Oregon 97504

Phone: 541-773-1435
Fax: 541-858-6828

www.touchstonepain.com

© OEA Brochures 2003-15 www.OEAbrochures.com